

ORAL MUCOCELE: A CASE REPORT

Dr. Rini Gangwal Badjatia*, **Dr. Sourabh Badjatia***, **Dr. Vinaya Kumar Kulkarni****, **Dr. Divya S. Sharma*****

Abstract:

Mucocele is a common lesion of the oral mucosa that results from an alteration of minor salivary glands due to a mucous accumulation causing limited swelling. Two histological types exist - extravasation and retention. Clinically they consist of a soft, bluish and transparent cystic swelling. This report presents an eight year old female patient having mucocele on lower lip. Treatment performed was surgical removal as she suffered difficulty in mastication & speech.

For this reason it was decided to deliberate the clinical characteristics of mucocele, and their treatment to aid for decision-making in daily clinical practice.

***Keywords:** Cyst, mucocele, mucous retention cyst, mucocele treatment, salivary gland.*

INTRODUCTION:

Mucocele is a common lesion of the oral mucosa that results from an alteration of minor salivary glands due to a mucous accumulation causing limited swelling.¹ Two types of mucocele can appear - extravasation and retention. Extravasation mucocele results from trauma to salivary glands duct and the consequent spillage into the soft tissues around this gland. Retention mucocele appears due to a decrease or absence of glandular secretion produced by blockage of the salivary gland ducts.² Mucoceles present a bluish, soft and transparent cystic swelling. The blue colour is caused by vascular congestion, and cyanosis of the tissue above and the accumulation of fluid below the mucosa.

*Senior Lecturer, **Professor, Department of Pedodontics & Preventive Dentistry, Modern Dental College & Research Centre, Indore .

Coloration can also vary depending on the size of the lesion, proximity to the surface and upper tissue elasticity.³ Lower lip is the most frequent site for mucocele. Tongue is the second most common location followed by the buccal mucosa and palate; rarely found in the retromolar region and posterior dorsal area of tongue.⁴

As mucocele is a common lesion and affects the general population. For this reason we felt it would be interesting to deliberate the clinical characteristics of mucoceles, and their treatment to aid for decision-making in daily clinical practice. This article describes a case of oral mucocele occurring on the lower lip.

CASE REPORT:

An eight year old female child presented with the chief complaint of Swelling on the lower lip (Figure 1).

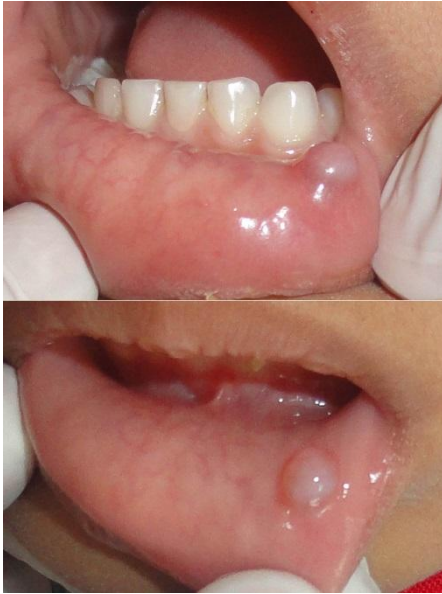

Fig 1: Intraoral view showing mucocele on the lower lip.

The history of present illness consisted of swelling on the lower lip since 1 month seen in the inner aspect of lower lip against teeth #73 and #74 region. The growth was of negligible size when the patient first noticed it, but had grown rapidly over the past one week to attain the present size. Patient gave history of trauma one month ago while mastication. The patient's medical and family history was not significant.

Clinical examination revealed the overlying mucosa was normal. Swelling was soft, fluctuant, palpable and non-tender with no increase in temperature, circular in shape measuring roughly 0.5x 0.5 cm² in size (Figure1).

The hemogram of the patient was within normal limits. Excision of the growth was performed under local anaesthesia (Figure 2 and 3). The surgical site was irrigated with povidone iodine - saline solution and closed primarily with 3-0 silk sutures. All post-operative instructions were given and analgesics were prescribed.

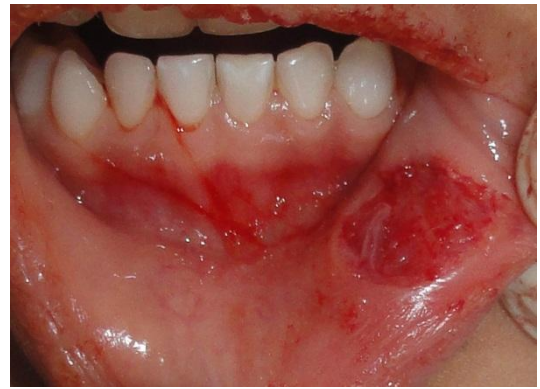

Fig 2: Intraoperative photograph showing Surgical Excision of Mucocele.

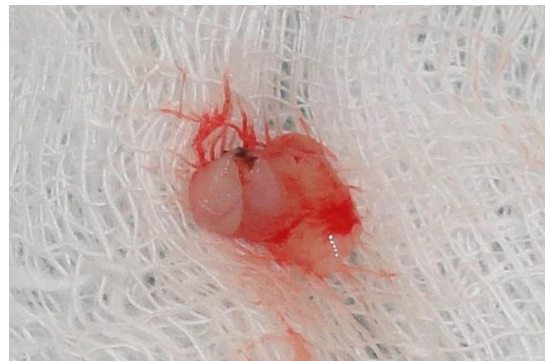

Fig 3: Excised tissue (Mucocele).

The specimen was placed in 10% formalin and sent for histo-pathological examination. One week later the sutures were removed, with normal healing being observed (Figure 4).

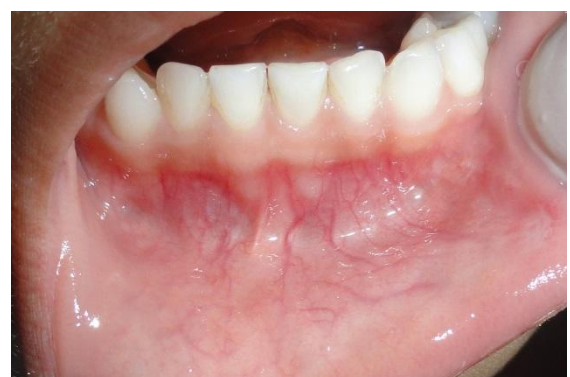

Fig 4: Uneventful healing of the surgical area after excision.

Histopathological examination (Figure 5) revealed para-keratinized stratified epithelium with few rete ridges.

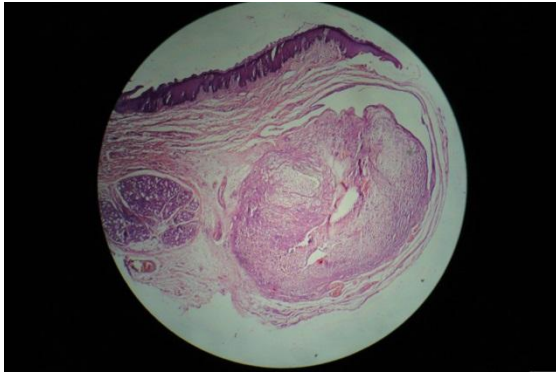


Fig 5: Confirmed the diagnosis by Histopathological examination.

The underlying connective tissue stroma shows presence of numerous salivary gland tissues along cystic space lined by inflammatory cell infiltration suggestive of mucous retention cyst (Mucocyst).

DISCUSSION:

Mucocysts are painless, asymptomatic swellings that have a relatively rapid onset and fluctuate in size. Mucocysts may be located either as a fluid-filled vesicle or blister in the superficial mucosa or as a fluctuant nodule deep within the connective tissue. Spontaneous drainage of the inspissated mucus especially in superficial lesions followed by subsequent recurrence may occur.⁵

The mechanism of formation of the mucocyst is still not totally clear; however, a traumatic etiology rather than an obstructive phenomenon is favoured. Chaudhry et al⁶ showed that the escape of mucus into the surrounding tissue after severing the excretory salivary ducts lead to the formation of the mucocyst. The most frequent occurrence of the mucocyst in the lateral aspect of the lower lip,⁷ a trauma-prone site. The present report also supports the role of trauma as an etiologic factor.

The development of mucocyst usually depends on the disruption of the flow of saliva from secretory apparatus of the salivary glands. The lesions are most often associated with mucus extravasation into the adjacent soft tissues caused by a traumatic ductal insult, which may include a crush-type injury of the excretory duct of the minor salivary gland.⁸

The incidence of mucocyst in the general population is 0.4-0.8%.⁹ As per age, the peak incidence is in the second or third decades of life, and as regards to location the lower lip is most frequently affected location (40-80% cases)¹⁰ followed by the cheek mucosa and floor of the mouth. The tongue, palate and upper lip are infrequent locations. These lesions in lower lip are more susceptible to accidental trauma or nibbling and suction habits.¹¹

The literature describes different treatment options, including cryosurgery,¹² intra-lesional corticosteroid injection,¹³ micro-marsupialization,¹⁴ conventional surgical removal,¹⁵ and laser ablation.¹⁶ Surgical excision with removal of the involved accessory salivary gland has been suggested as the treatment. Baurmash³ proposes complete resection of the mucocyst through careful dissection, and ensuring that both the affected and neighbouring glands are removed, along with the pathological tissue, before primary closure of the wound. This minimizes the risk of relapse. Special care is required to avoid damaging other glands or ducts with the suture needle, since this may become a cause of recurrence. The excised tissue should always be submitted to the pathological investigations to confirm the diagnosis and rule out the salivary gland tumors. The various differential diagnosis are Blandin and

Nuhn mucocele, Ranula, Benign or malignant salivary gland neoplasms, Oral lymphoepithelial cyst, Gingival cyst in adults.^{4,5}

CONCLUSION:

Mucocele are relatively common salivary gland cyst. Its recurrence rate is rare if the involved accessory salivary glands are removed. Care must be taken to eliminate the causative agent along with the surgical excision of the lesion.

REFERENCES:

1. Bagan Sebastian JV, Silvestre Donat FJ, Penarrocha Diago M, Milian Masanet MA. Clinico-pathological study of oral mucoceles. *Av Odontostomatol* 1990;6:389-91, 394-5.
2. Boneu BF, Vidal HE, Maizcurrana TA, Gonzalez LJ. Submaxillary gland mucocele: presentation of a case. *Med Oral Patol Oral Cir Bucal* 2005;10:180-4.
3. Baurmash HD. Mucoceles and ranulas. *J Oral MaxillofacSurg* 2003;61:369-78.
4. Neville BW, Damm DD, Allen CM, Bouquot JE. *Oral and maxillofacial pathology*. 2nded. New Dehli: Reed Elsevier India Pvt Ltd; 2004. p.389-91
5. Mc Donald, Avery &Dean: *Dentistry for the child and adolescent*, 8thedition, Mosby, 2004.
6. Chaudhry AP, Reynolds DH, Lachapelle CF, Vickers RA. A clinical and experimental study of mucocele. *J Dent Res* 1960;39:1253-62
7. Shivapathasundharam B. Physical and chemical injuries of the oral cavity. In: Rajendran R, Shivapathasundharam B, editor. *Shafer's Textbook of Oral Pathology*, 6thed. Noida: Elsevier; 2009. p. 517-69.
8. Shear M. Cysts of the salivary glands. In: Shear M, editors. *Cysts of The Oral and Maxillofacial Regions*, 4thed. Oxford: Blackwell Munksgaard; 2007. p. 171-80.
9. Anastassov GE, Haiavy J, Solodnik P et al. Submandibular gland mucocele: diagnosis and management. *Oral Surg Oral Med Oral Pathol Oral RadiolEndod* 2000;89(2):159-63
10. Knapp MJ. Oral disease in 181,338 consecutive oral examinations. *J Am Dent Assoc.* 1971;83:1288-93.
11. Harrison JD. Salivary mucoceles. *Oral Surg Oral Med Oral Pathol*1975;39:268-78.
12. Silva AJr, Nikitakis NG, Balciunas BA, Meiller TF. Superficial mucocele of the labial mucosa: a case report and review of the litera-ture *Gen Dent.* 2004;52:424-7.
13. Twetman S, Isaksson S. Cryosurgical treatment of mucocele in children. *Am J Dent* 1990;3:175-6.
14. Wilcox JW, History JE. Nonsurgical resolution of mucoceles. *J Oral Surg*1978;36:478.
15. Delbem AC, Cunha RF, Vieira AE, Ribeiro LL. Treatment of mu -cus retention phenomena in children by the micro-marsupialization technique: case reports. *Pediatr Dent* 2000;22:155-8.
16. Ata-Ali J, Carrillo C ,Bonet C , Balaguer J, Penarrocha M , Penarrocha M. Oral mucocele: review of the literature. *J ClinExp Dent* 2010;2(1):18-21.

Corresponding Author

Dr Rini Gangwal Badjatia,

Department of Pedodontics & Preventive Dentistry, Modern Dental College & Research Centre, Indore.

E-mail-dr.rini.gangwal@gmail.com